

## Evaluating an Ultrasound Algorithm for Patients with Blunt Abdominal Trauma

Ara J. Feinstein, MD, Mark G. McKenney, MD, Stephen M. Cohn, MD

Ryder Trauma Center, Department of Surgery  
University of Miami School of Medicine, Miami, FL  
1800 NW 10<sup>th</sup> Ave. Suite 215, Miami, FL 33136  
Tel: 305-585-1178, Fax: 305-243-7354

E-mail: [mmckenne@med.miami.edu](mailto:mmckenne@med.miami.edu)

### ABSTRACT

*The ideal assessment of the blunt abdominal trauma (BAT) patient would be sensitive, specific, economical, fast, and without complications. By combining ultrasound (US) with computed tomography (CT) and diagnostic peritoneal lavage (DPL), an effective algorithm can be derived to accurately evaluate BAT. We prospectively evaluated a series of patients with suspected blunt abdominal trauma using an algorithm with ultrasound as the initial screening modality to determine if it would be more sensitive, specific, and cost-effective than each diagnostic modality alone. **Methods:** One hundred ninety-one patients over the age of 18 with suspected BAT were evaluated according to an established algorithm. Ultrasound was the initial diagnostic technique. **Results:** In this study, US had a sensitivity of 84.0%, a specificity of 98.7, and an accuracy of 96.7%. CT had a sensitivity of 100%, a specificity of 100% and an accuracy of 100%. The algorithm had a sensitivity of 100%, a specificity of 98.7% and an accuracy of 99.0%. Of the patients entered in the study, 9% received a laparotomy. The non-therapeutic laparotomy rate was 11%. **Conclusions:** An algorithm for blunt abdominal trauma that utilizes ultrasound as the initial diagnostic technique can accurately assess intrabdominal hemorrhage in unstable patients and act as a screening tool for computed tomography in stable patients.*

### 1.0 INTRODUCTION

Fifty-seven million people become trauma victims every year in the United States, making it a significant cause of morbidity and mortality. Trauma is the fourth leading cause of death in the United States overall and the most common cause of death in people under the age of 44. Approximately 20% of injured trauma victims will have residual long-term disabilities.<sup>1,2</sup>

Injuries related to blunt abdominal trauma (BAT) may follow direct impact, acceleration-deceleration, and shearing forces to the human body.<sup>3</sup> These occur most commonly from automobile collisions, followed by falls and assaults. In motor vehicle collisions and falls, the process of rapid deceleration creates a situation where the body's internal organs continue moving after the musculoskeletal system has been stopped.

The evaluation of patients with suspected blunt abdominal trauma presents a diagnostic challenge. Patients often do not present with the classic signs of intraabdominal injury such as abdominal pain or unexplained hypotension. In addition, trauma centers often have a high proportion of patients with an altered mental status due to chemical substances or head injury, making the clinical history and physical exam less reliable.<sup>4</sup>

*Paper presented at the RTO HFM Symposium on "Combat Casualty Care in Ground Based Tactical Situations: Trauma Technology and Emergency Medical Procedures", held in St. Pete Beach, USA, 16-18 August 2004, and published in RTO-MP-HFM-109.*

In the past, all patients with suspected intraabdominal injury were surgically explored. With this strategy, negative laparotomies, in which no injury is found, resulted in morbidity 18% of the time and non-therapeutic laparotomies, in which there is no surgical intervention for intraabdominal injuries, resulted in a morbidity rate of 45%.<sup>5</sup> Exploratory laparotomy following BAT still remains mandatory for certain patients (peritonitis, free air, progressive abdominal distention with unexplained hypotension), but in the absence of these more overt clinical findings several modalities are typically utilized to increase diagnostic accuracy.

In 1965 Root introduced diagnostic peritoneal lavage (DPL).<sup>6</sup> DPL is a relatively fast procedure, being performed in 3-26 minutes.<sup>7,8</sup> It can be performed during trauma resuscitations with a sensitivity of 87-99% and a specificity of 97-98%.<sup>9,10,11</sup> The procedure requires peritoneal puncture and is associated with only a 1% incidence of significant complications but it is unable to adequately detect retroperitoneal and diaphragmatic injury.<sup>12,13</sup> DPL is relatively contraindicated in pregnant patients, those with multiple previous operations, pelvic fractures, or clotting disorders.

Computed tomography is increasingly utilized in BAT patients since it is a non-invasive test and has a sensitivity of up to 97% and a specificity 98-99%.<sup>14,15</sup> CT permits localization and grading of injuries, but cannot be safely performed on unstable or uncooperative patients due to the requirement for transport to the radiology suite and time constraints.<sup>16</sup> CT can take 60 – 90 minutes to obtain when transport and setup times are included<sup>17</sup> with a cost that is considerably higher than other diagnostic modalities.<sup>18,19</sup> CT also carries the risk of complications from intravenous contrast injection and allergy.

The use of ultrasound in the United States has become increasingly popular among trauma surgeons for providing a quick, reliable assessment of the thorax and abdomen in BAT. Numerous publications, including one with 1000 patients examined prospectively,<sup>20</sup> have described its speed, portability, and low-cost in this patient population.<sup>21,22</sup> It has also been shown repeatedly that housestaff can interpret US results as reliably as radiology personnel.<sup>23,24,25</sup>

The ideal assessment of the BAT patient would be sensitive, specific, economical, fast, and without complications. By combining ultrasound with computed tomography (CT) and diagnostic peritoneal lavage (DPL), a potentially cost effective algorithm can be derived to accurately evaluate blunt abdominal trauma patients. We prospectively evaluated a series of patients with suspected blunt abdominal trauma using an algorithm with ultrasound as the initial screening modality to determine if it would be more sensitive, specific, and cost-effective than each diagnostic modality alone.

## 2.0 PATIENTS AND METHODS

This study was conducted at the Ryder Trauma Center, Jackson Memorial Hospital. This is the only Level I trauma facility for all of Dade County, Florida. The study was approved by the Institutional Review Board at Jackson Memorial Hospital. Five hundred eighty-five patients were seen over a two-month period ending in August 1996. One hundred ninety-one patients over the age of 18 with suspected BAT, in which physical examination alone would not be sufficient to completely assess intraabdominal injuries, were evaluated according to an established algorithm (figure 1). The remaining 398 patients were evaluated with physical examination alone and were not included in the study.

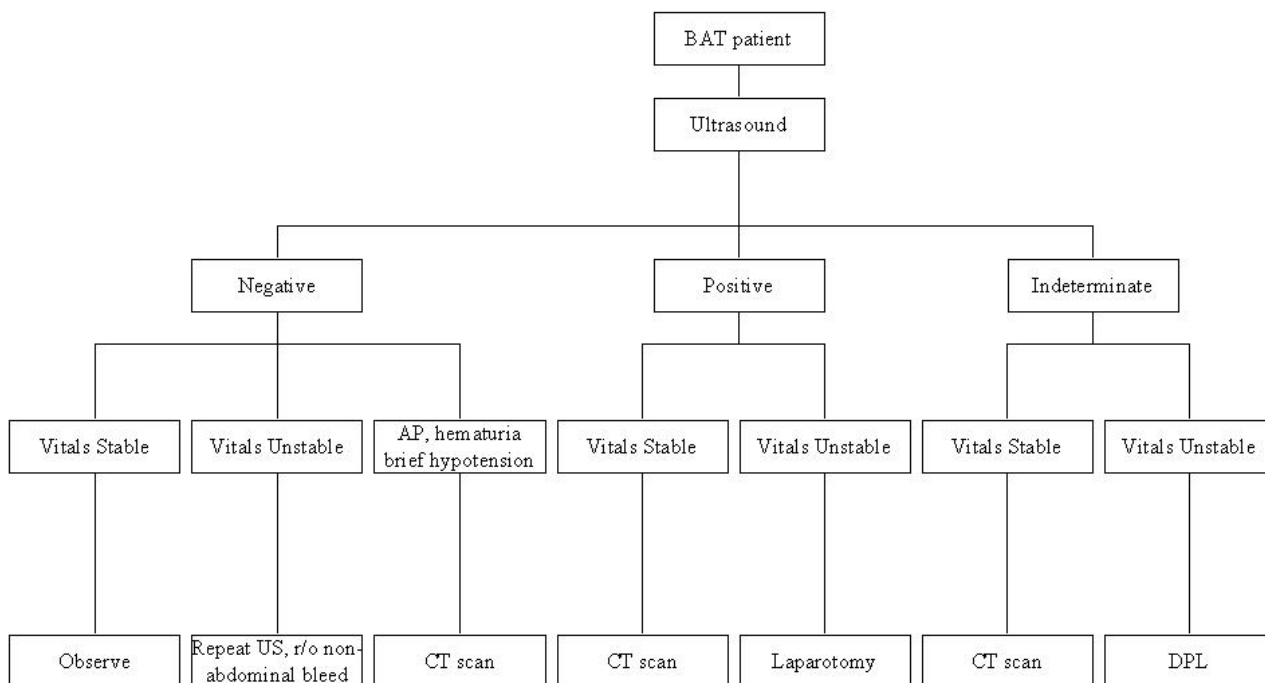
Ultrasound was the initial diagnostic technique in all 191 patients. If the US examination was negative, the patients were initially observed. If the patient showed no further BAT related symptoms (hypotension, abdominal pain, hematuria), the assessment for BAT was terminated. Hemodynamically stable patients that

developed hematuria, transient hypotension, or abdominal pain during observation received a CT scan. If a patient under observation developed persistent hypotension, a repeat ultrasound was performed. If the initial US was positive, stable patients received a CT examination to further evaluate and grade the injury, while unstable patients were taken for exploratory laparotomy. If the US was deemed indeterminate and the patient was stable, a CT scan was performed. In unstable patients with an indeterminate US, DPL was performed. At any time during the BAT work-up, a patient could be taken to the operating room if they developed peritoneal signs on physical examination.

The following definitions were used for the algorithm: 1) true positive- an injury was detected and confirmed by another diagnostic technique or laparotomy, 2) true negative- if no injury was detected by the techniques and none developed later, 3) false positive- a non-therapeutic exploratory laparotomy, 4) false negative- passage through the algorithm without a detected injury and a subsequent laparotomy revealing intraabdominal injury. At anytime during the diagnostic workup, the surgeon could interrupt the algorithm for laparotomy based on clinical judgment. This was considered as a positive diagnosis of intraabdominal injury according for the algorithm and resulted in a false positive for the algorithm if the laparotomy was negative.

US was performed by dedicated technologists using an Accuson 128x P/10 (Mountain View, California) with a 3.5-MHz sector or curvilinear transducer to identify free fluid in six areas as previously described: the pericardium, the subphrenic space bilaterally, splenic tip, subhepatic space, and the pelvis. The liver and spleen were also evaluated for parenchymal injury. An attending radiologist or senior radiology resident interpreted all scans. The US or CT was deemed positive if free fluid or a parenchymal injury was clearly identified. A negative US or CT was recorded when no visceral injury and no free intraperitoneal fluid was found. The US or CT examination was deemed indeterminate if there was questionable free fluid, questionable visceral injury, or if the examination was technically limited. A DPL was ruled positive if there was one or more of the following 1) initial aspirate yielded > 5cc of blood, 2) RBC > 100,000 RBCs/mm<sup>3</sup> or, 3) WBC > 500 WBC/mm<sup>3</sup>.

Figure 1: Experimental Algorithm



Key: AP = abdominal pain, US = ultrasound, CT = computed tomography

### 3.0 RESULTS

A total of 191 patients with BAT were evaluated with the algorithm over a two-month period (figure 2). One hundred and fifty-nine of these patients had a negative US, 23 patients had a positive US, and 9 patients had an indeterminate result.

All 159 patients with a negative US were admitted for observation. One hundred and forty-three of these patients received no further tests. One patient developed persistent hypotension and received a second US with a negative result. Further evaluation revealed major thoracic injuries as the cause of hypotension, with no intraabdominal injury. Fifteen patients with a negative US had persistent abdominal pain or transient hypotension. One patient was taken to the operating room after abdominal pain progressed to peritoneal signs (table 1). Operative findings revealed a jejunal injury. Fourteen negative US patients received a CT scan. Eleven had a negative CT. Three patients had a positive CT scan with missed injuries that were managed non-operatively. In this group, one patient had a subcapsular hematoma of the liver with no free fluid present, the second patient had a splenic laceration with a small amount of perisplenic fluid, and the third patient had a liver laceration with a small amount of perihepatic fluid. The overall negative predictive value of US was 97% (155 TN / 155 TN + 4FN).

Twenty-three of the total 191 patients had a positive US result. Twelve initially had stable vital signs, and received a follow up CT. In 2 patients, the US was deemed positive and the CT negative. One patient had stable vital signs but persistent abdominal pain. The patient subsequently developed peritoneal signs and was taken for exploratory laparotomy in which no free fluid or organ injury was identified. The abdominal pain was determined to be referred pain from lower rib fractures and the patient was counted as a false positive in the algorithm. The other patient with a positive US and negative CT was observed with no subsequent evidence of intraabdominal injury. Ten patients had positive CT scans after positive US. Four of these patients became hypotensive later and were taken to the operating room and found to have intraabdominal injuries, while the other six were managed non-operatively.

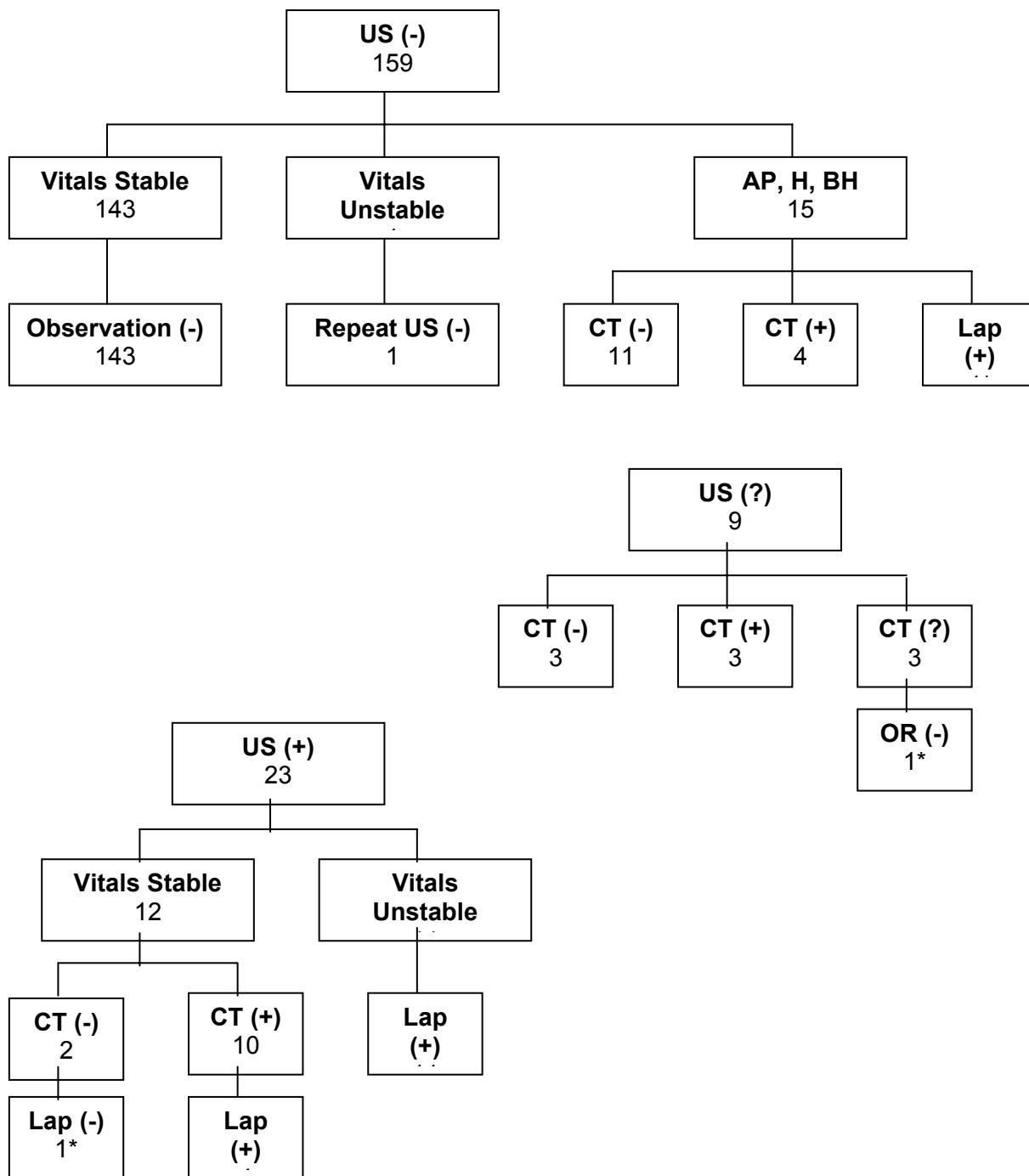
Eleven patients had a positive US and unstable vital signs, and were taken directly to the operating room. All eleven of these patients were found to have intraabdominal injuries. The overall positive predictive value of US was 91% (21 TP / 21 TP + 2 FP).

Nine patients had an indeterminate or questionably positive US result. All of these patients were hemodynamically stable and were evaluated with CT. Three out of the 9 indeterminate patients had a negative CT with no subsequent injury while three patients had a positive CT with non-operative injuries. These injuries were a grade 3 liver laceration, a grade 2 liver laceration, and a large subcapsular hematoma. Three patients had an indeterminate CT. Two were observed and one had an exploratory laparotomy that showed a hematoma on the sub-diaphragmatic aorta.

In this study, US had a sensitivity of 84.0% (21 TP/ 21 TP + 4 FN), a specificity of 98.7% (155 TN/ 155 TN + 2 FP), and an accuracy of 96.7% (155 TN + 21 TP / 21 TP +155 TN + 2 FP + 4 FN). CT had a sensitivity of 100% (13 TP/ 13 TP + 0 FN), a specificity of 100% (17 TN/ 17 TN + 0 FP) and an accuracy of 100% (17 TN + 13 TP / 17 TN +13 TP + 0 FN + 0 FP). The algorithm had a sensitivity of 100% (28 TP/ 28 TP + 0 FN), a specificity of 98.7% (161 TN/ 161 TN + 2 FP) and an accuracy of 99.0% (161 TN + 28 TP / 28 TP +161 TN + 0 FN + 2 FP). Of the patients entered in the study, 9% received a laparotomy. The non-therapeutic laparotomy rate was 11%.

# Evaluating an Ultrasound Algorithm for Patients with Blunt Abdominal Trauma

Figure 2: Algorithm Results



Key: US = ultrasound, CT = computed tomography, Lap = laparotomy, (+) = positive, (-) = negative, (?) = indeterminant, AP= abdominal pain, H = hematuria, BH = brief hypotension  
 \* patient taken for laparotomy based on clinical findings

**Table 1: Patients undergoing laparotomy**

	U S	US results	C T	CT result	O R	OR result (procedure)
1	-		X		+	Small bowel injury (resection)
2	+	Fluid in Morrison's pouch; liver laceration	X		+	Bladder injury (repair); liver laceration (hepatorraphy)
3	+	Abundant free fluid in abdomen	X		+	Splenic hilar injury (splenectomy); Liver subcapsular hematoma
4	+	Abundant free fluid in abdomen; liver laceration	X		+	Splenic laceration (splenorrhaphy); Liver laceration (hepatorraphy)
5	+	Pelvic, perisplenic, subhepatic fluid	X		+	Liver laceration (hepatorraphy)
6	+	Fluid in abdomen and pelvis	X		+	Liver laceration (hepatorraphy); vena cava injury (repair)
7	+	Perihepatic, perisplenic, pelvic fluid	X		+	Mesenteric injury (ligation of bleeding vessel)
8	+	Abundant free fluid in abdomen	X		+	Splenic injury (splenectomy)
9	+	Free fluid in abdomen; splenic laceration	X		+	Splenic injury (splenectomy); Liver injury (hepatorraphy)
10	+	Abundant free fluid in abdomen	X		+	Splenic injury (splenectomy)
11	+	Perisplenic fluid	X		+	Splenic injury (splenectomy)
12	+	Fluid in Morrison's pouch, splenic parenchymal injury	X		+	Liver laceration (hepatorraphy); splenic laceration (splenectomy)
13	+	Liver laceration, fluid in Morrison's pouch	+	Liver laceration; paracolic fluid	+	Liver laceration (hepatorraphy)
14	+	Fluid in Morrison's pouch	+	Subhepatic fluid	+	Splenic subcapsular hematoma (splenorrhaphy)
15	+	Perisplenic fluid	+	Free fluid in abdomen, pelvis; fractured spleen	+	Splenic injury (splenectomy)
16	+	Perisplenic, subhepatic fluid; splenic parenchymal injury	+	Abundant free fluid; shattered spleen	+	Splenic injury (splenectomy)
17	+	Fluid in Morrison's pouch; perisplenic fluid	-	Rib fractures	-	No intraabdominal injury
18	?	Liver laceration	?	Diaphragm rupture; aortic aneurysm	-	Hematoma superficial to aorta

(+) = positive test, (-) = negative test, (?) = indeterminate test (X) = not performed



### 4.0 DISCUSSION

The principle finding of this study is that an algorithm utilizing ultrasound is 100% sensitive and 99% specific for detecting injury in blunt abdominal trauma. It is also cost-effective and results in a low rate of non-therapeutic laparotomy.

These results compare favorably with other algorithms used to assess BAT patients. Mele et al. examined an algorithm with CT and DPL with no missed injuries and no non-therapeutic laparotomies.<sup>26</sup> Bode et al. utilized a protocol with US and CT in 1,671 BAT patients with no non-therapeutic laparotomies, but two missed injuries were discharged home.<sup>27</sup> Shih et al. used a diagnostic algorithm with CT and US and had two non-therapeutic laparotomies and no missed injuries. Boulanger et al. compared an algorithm similar to the one described here to an algorithm utilizing only CT and DPL and showed no difference in diagnostic accuracy between the two groups.<sup>28</sup> The algorithm utilizing US however, had a significantly faster work-up time and lower cost.

We have found that US is best used in two situations. In stable patients, US potentially serves as an extension of the physical examination and therefore may act as a triage for CT. Because CT is highly sensitive, many would argue that it be used as the primary diagnostic technique for the assessment of BAT patients. This is problematic because CT is expensive with a hospital cost of around \$500 per scan. CT is also time consuming and necessitates approximately 60-90 minutes of direct patient care if transport and setup time are considered. Time can be an important factor in centers where demand for CT exceeds the available scanning time. By using CT based on our algorithm, 145 scans were avoided during the study period. Over two-months, this resulted in a cost savings of approximately \$72,000.

Ultrasound missed 4 injuries in stable patients during the study. Three were non-operative solid organ injuries discovered by CT. Solid clots can have similar echogenicity to surrounding tissue, and this contributes significantly to the greater sensitivity of CT over ultrasound. The remaining patient had a small bowel injury, and this injury was detected with physical examination. The ability of US to detect isolated hollow viscous injury is poor, since often no free fluid is present initially. Similarly, CT and DPL have a relatively low rate of detection in this type of injury and physical examination findings continue to be an important indicator for bowel injury in the BAT patient. Ultrasound findings were falsely positive in two stable patients, but they did not undergo laparotomy because they were hemodynamically stable and their follow-up CT was negative.

The second indication for US in BAT is for unstable patients. Ultrasound can quickly assess if the injury is intraabdominal or if other body compartments such as the thorax, pelvis, or head should be the focus of diagnostic work-up. These patients cannot safely undergo CT scanning because access to the patient by healthcare providers for continued resuscitation becomes problematic. These types of patients previously received a DPL during their initial trauma evaluation and resuscitation.

All positive ultrasounds in unstable patients were confirmed by laparotomy. There was one negative US in an unstable patient who was shown to have a thoracic injury. This highlights the utility of US in the unstable patient. Before proceeding directly to the laparotomy, the surgical team needs to be aware of whether an intraabdominal injury is present.

DPL was not used in the study, although it was included in the algorithm. No patients met criteria for DPL, but the option should be maintained for unstable patients with indeterminate US. CT proved to be 100%



sensitive and specific when used after US screening. There was one negative laparotomy in the study. This patient had all tests negative but was taken to the OR on the basis of physical examination findings and was shown to have no intraabdominal injuries.

A potential weakness of this study is that patients that were not considered to have an injury were observed only until discharge. Although no patient that was discharged presented with subsequent injuries to our center or clinic, it is possible that they may have sought care elsewhere. In addition, the study was conducted prospectively but without randomization of patients to a comparative clinical pathway or a control group. This needs to be addressed in future studies.

This study demonstrates that US offers the clinician a number of advantages in the assessment of BAT patients. All BAT patients, including those that are hemodynamically unstable and those with an altered mental status can be quickly scanned during the resuscitation to give the physician an immediate indicator if intraabdominal hemorrhage is present. Those with a negative US and no other symptoms or abnormal findings can be safely discharged after an observation period. Those with positive US results can be taken immediately for laparotomy if they are hemodynamically unstable. The CT scan can then be reserved for stable patients with a positive US in order to better characterize the injury or for symptomatic patients with a negative US. This is financially and clinically sound because it greatly reduces the number of CT scans while identifying injuries US is more likely to miss such as confined solid organ hematomas and bowel injuries.

We conclude that an algorithm for blunt abdominal trauma that utilizes ultrasound for unstable patients and as a screening tool for CT in stable patients is highly economical and is an accurate method for detecting intraabdominal injury.

### 5.0 REFERENCES

- [1] Singh GK, Kochanek KD, MacDorman MF. 1996. Advance report of final mortality statistics, 1994. *MVSR*. 45(suppl 3):1-80.
- [2] Rice RP, MacKenzie EJ and Associates. 1989. *Cost of Injury in the United States*. San Francisco, California: Institute for Health and Aging, University of California and, Injury Prevention Center, The Johns Hopkins University: 7-37.
- [3] Thal ER, Meyer DM. 1991. The evaluation of blunt abdominal trauma: computed tomography scan, lavage, or sonography? *Adv Surg*. 24:201-28.
- [4] Perry JF Jr. 1965. A five-year survey of 152 acute abdominal injuries. *J Trauma*. 5:53-61.
- [5] Renz BM, Feliciano DV. 1995. Unnecessary laparotomies for trauma: a prospective study of morbidity. *J Trauma*. 38(3):350-6.
- [6] Root HD, Hauser CW, McKinley CR. 1965. Diagnostic peritoneal lavage. *Surgery*. 57:633.
- [7] Meyer DM, Thal ER, Weigelt JA, Redman HC. 1989. Evaluation of computed tomography and diagnostic peritoneal lavage in blunt abdominal trauma. *J Trauma*. 29:1168.
- [8] Hawkins ML, Bailey RL Jr, Carraway RP. 1990. Is diagnostic peritoneal lavage for blunt abdominal trauma obsolete? *Am Surg*. 56:96.
- [9] Alyono D, Morrow CE, Perry JF. 1982. Reappraisal of diagnostic peritoneal lavage criteria for operation in penetrating and blunt trauma. *Surgery*. 92:751.
- [10] Gomez GA, Alvarez R, Plasencia G. 1987. Diagnostic peritoneal lavage in the management of blunt abdominal trauma: A reassessment. *J Trauma*. 27:1.

- [11] Henneman PL, Marx JA, Moore EE. 1990. Diagnostic peritoneal lavage: accuracy in predicting necessary laparotomy following blunt and penetrating trauma. *J Trauma*. 30:1345.
- [12] Powell DC, Bivins BA, Bell RM. 1982. Diagnostic peritoneal lavage. *Surg Gynecol Obstet*. 155: 257-64.
- [13] Soderstrom CA, DuPriest RW, Cowley RA. 1980. Pitfalls of peritoneal lavage in blunt abdominal trauma. *Surg Gynecol Obstet*. 151: 513-8.
- [14] Pietzman AB, Makaroun MS, Slasky BS. 1986. Prospective study of computed tomography in initial management of blunt abdominal trauma. *J Trauma*. 26:585.
- [15] Shuman, W.P. 1997. CT of blunt abdominal trauma in adults. *Radiology*. 205(2):297-306.
- [16] Hoffmann R, Nerlich M, Muggia-Sullam M., Pohlemann T, Wippermann B, et al. 1992. Blunt abdominal trauma in cases of multiple trauma evaluated by ultrasonography: a prospective analysis of 291 patients. *J Trauma*. 32:452-8.
- [17] Troop B, Fabian T, Alsup B, Kudsk K. 1991. Randomized, prospective comparison of open and closed peritoneal lavage for abdominal trauma. *Ann Emerg Med*. 20:1290.
- [18] McKenney M, Lentz K, Nunez D, Sosa JL, Sleeman D, et al. 1994. Can ultrasound replace diagnostic peritoneal lavage in the assessment of blunt trauma? *J Trauma*. 37: 439-41.
- [19] McKenney KL, McKenney M, Nunez D, Martin L. 1997. Cost reduction using ultrasound in blunt abdominal trauma. *Emerg Rad*, 4: 3-9.
- [20] McKenney MG, Martin L, Lentz K, Lopez C, Sleeman D, et al. 1996. 1,000 consecutive ultrasounds for blunt abdominal trauma. *J Trauma*. 40:607-10.
- [21] Kimura A., Otsuka T. 1989. Emergency center ultrasonography in the evaluation of hemoperitoneum: A prospective study. *J Trauma*. 31(1):20-3.
- [22] Tso P, Rodriguez A, Cooper C, Militello P, Mirvis S, et al. 1992. Sonography in blunt abdominal trauma: A preliminary progress report. *J Trauma*. 33:39-43.
- [23] Rozycki GS, Ochsner MG, Jaffin JH, Champion HR. 1993. Prospective evaluation of surgeons' use of ultrasound in the evaluation of trauma patients. *J Trauma*. 34:516-26.
- [24] Ma OJ, Mateer JR, Ogata M, Kefer MP, Wittmann D, Aprahamian C. 1995. Prospective analysis of a rapid trauma ultrasound examination performed by emergency physicians. *J Trauma*. 38:879-85.
- [25] McKenney MG, McKenney KL, Compton RP, Namias N, Fernandez L, Levi D, Arrillaga A, Lynn M, Martin L. 1998. Can surgeons evaluate emergency ultrasound scans for blunt abdominal trauma? *J Trauma*. 44:649-53.
- [26] Mele TS, Stewart K, Marokus B, O'Keefe GE. 1999. Evaluation of a diagnostic protocol using screening diagnostic peritoneal lavage with selective use of abdominal computed tomography in blunt abdominal trauma. *J Trauma*. 46(5):847-52.
- [27] Bode PJ, Edwards MJ, Kruit MC, van Vugt AB. 1999. Sonography in a clinical algorithm for early evaluation of 1671 patients with blunt abdominal trauma. *AJR Am J Roentgenol*. 172(4):905-11.
- [28] Boulanger BR, McLellan BA, Brenneman FD, Ochoa J, Kirkpatrick AW. 1999. Prospective evidence of the superiority of a sonography-based algorithm in the assessment of blunt abdominal injury. *J Trauma*. 47(4):632-7.